



London Sports
Orthopaedics





Ski Injuries – It's not over yet! Vista Diagnostics March 2018

Mark Phillips

Consultant Orthopaedic & Trauma Surgeon
(*Hand & Wrist*)

London Bridge Hospital

part of **HCA**Healthcare UK





The Knee Team



Mr Ian McDermott



Mr Paul Jairaj



Mr Henry Atkinson



Mr Peter Hill



Mr Vipin Asopa



The Upper Limb & Hand Team



Mr Mark Phillips



Mr Livio Di Mascio



Mr Adrian Carlos



The Spine Team



Mr Alexander Montgomery



Mr Hanny Anwar



Mr Ahmed Ibrahim




Dr Ben Huntley



The Foot & Ankle Team



Mr Ali Abbasian




Mr Aria Ghassemi



SEM / Rheumatology / Pain



Dr Kal Parmar



Dr Simon Paul



Dr Ben Huntley



London Sports
Orthopaedics



London Bridge Hospital

part of **HCA**Healthcare uk



London Sports
Orthopaedics



London Bridge Hospital

part of **HCA**Healthcare uk



London Sports Orthopaedics



The Sports Orthopaedics Research Foundation

From excellence in academia and research to excellence in clinical practice

The Sports Orthopaedics Research Foundation is committed to the study and development of excellence in modern clinical Orthopaedic and Sports Injury practice through the promotion of training, education, audit and research. The Foundation is an organization established in 2010 and developed by the Specialist Consultants from the practices in the Sports Orthopaedics UK Group.

[Read more](#)

SPORTS ORTHOPAEDICS
RESEARCH FOUNDATION



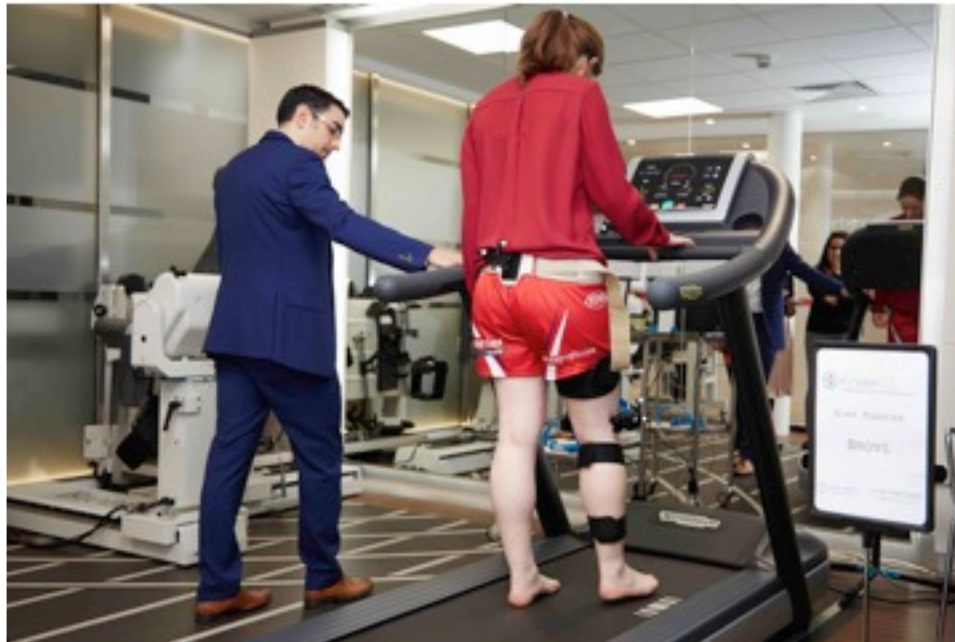London Sports
Orthopaedics



SPORTS ORTHOPAEDICS
RESEARCH FOUNDATION



London Sports
Orthopaedics



SPORTS ORTHOPAEDICS
RESEARCH FOUNDATION

Wrist pain after winter sports injuries – it is not over yet...!

- What is the differential diagnosis?
- Fracture or no fracture?

Hand & wrist injuries in winter sports

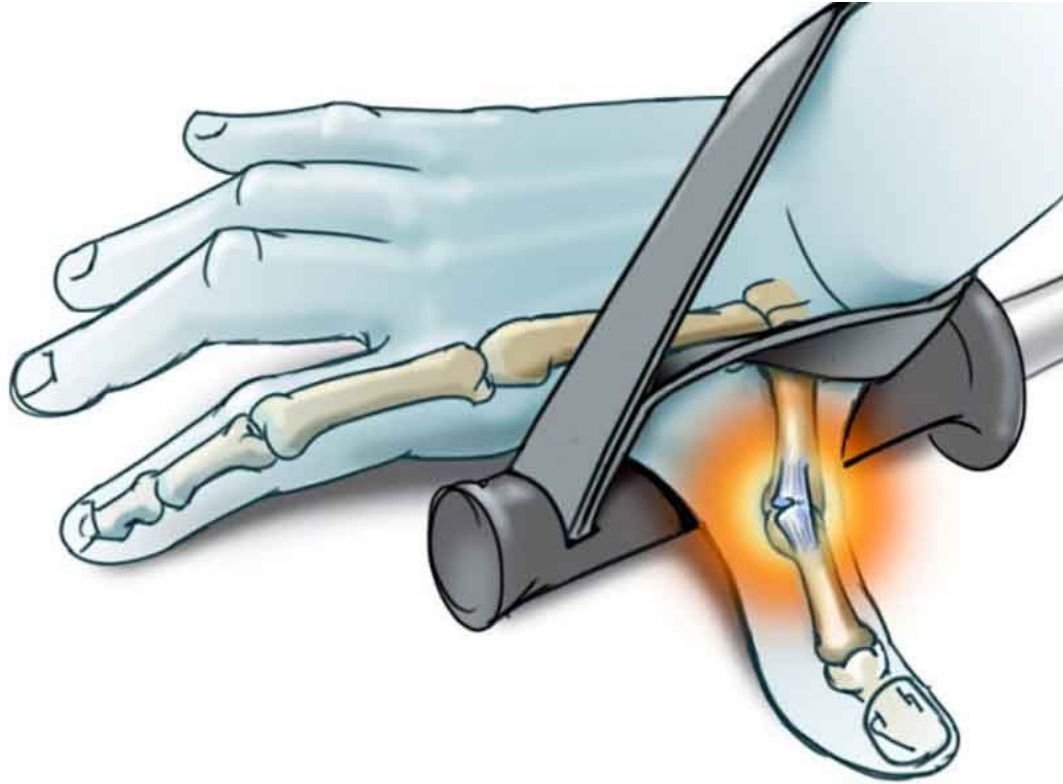- 25% of skiing injuries
- 50% of snowboarding injuries
- 90% of skating injuries



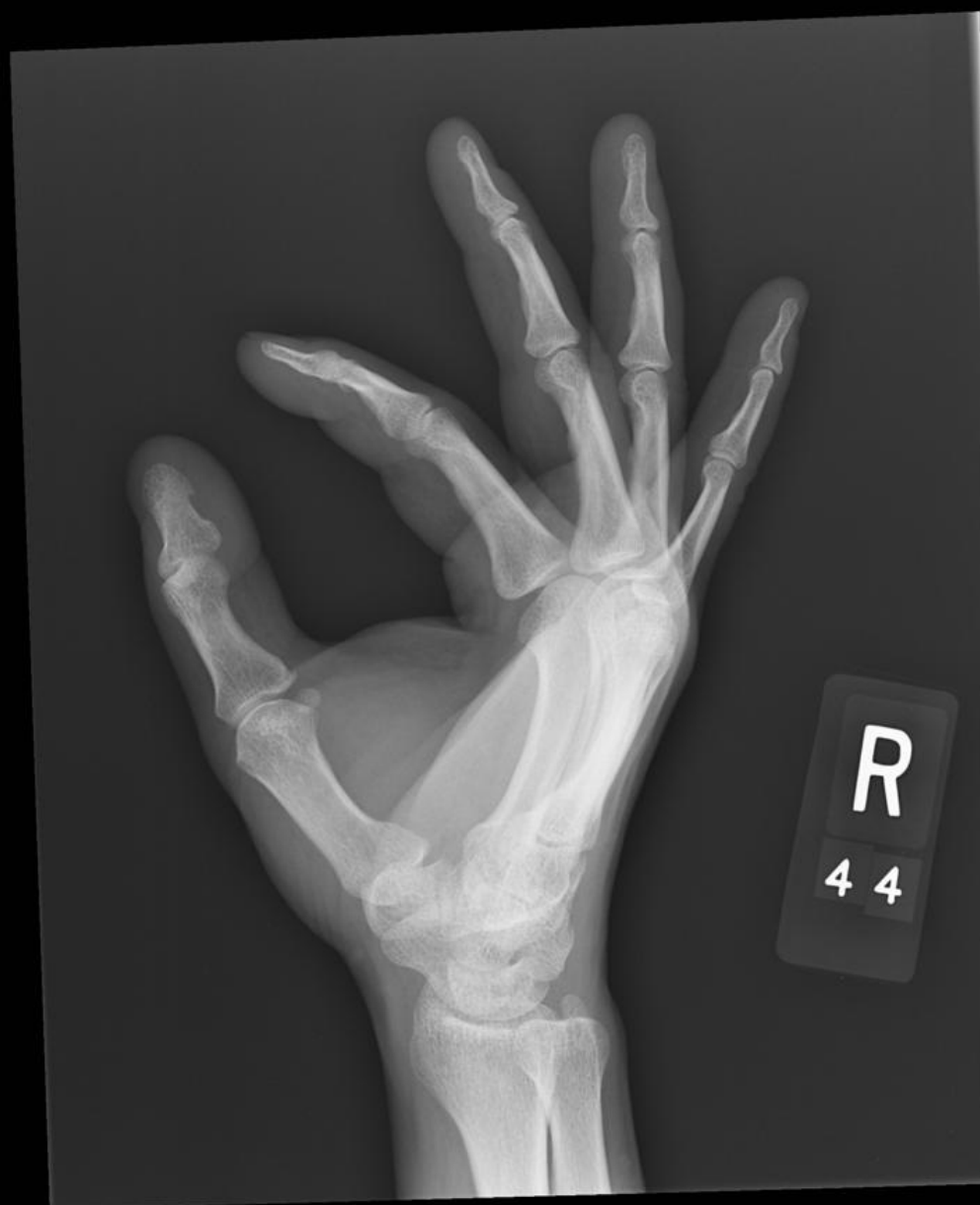Fractures

- Colles
- Other distal radial
- Scaphoid
- Hand fractures
- Skiers thumb

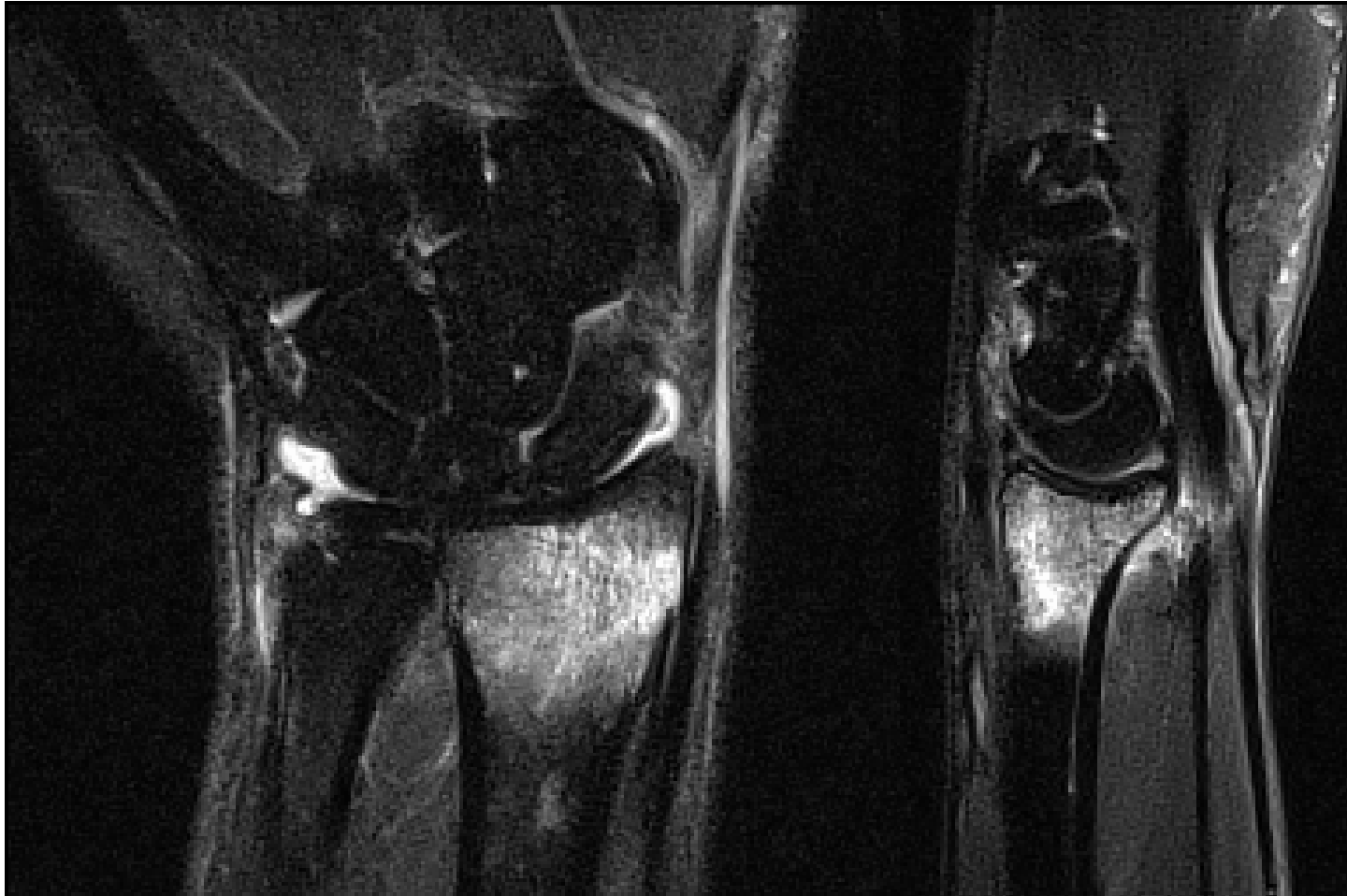
Skier's thumb



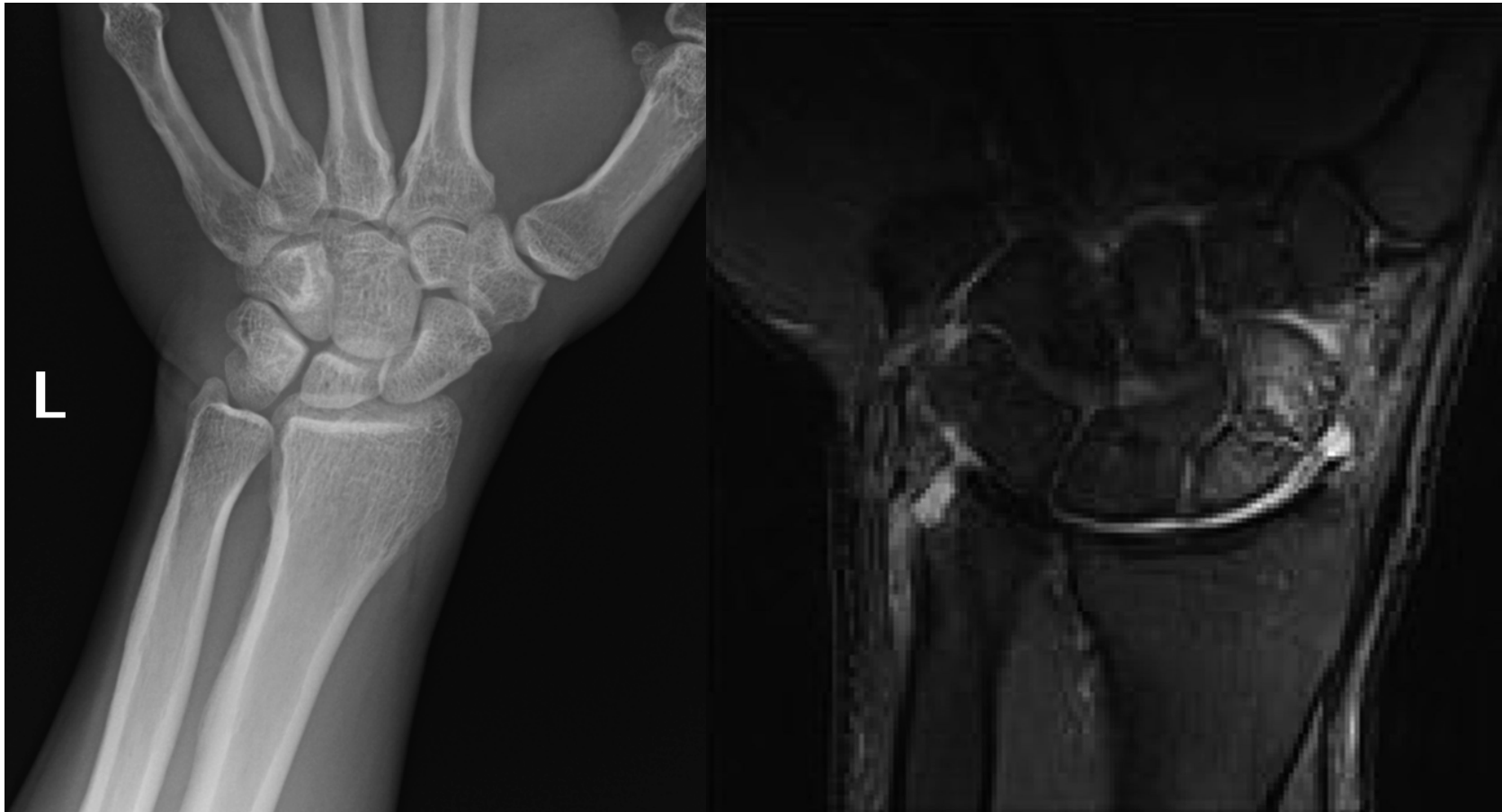
Warning: Not for diagnostic use



Distal radial occult fracture



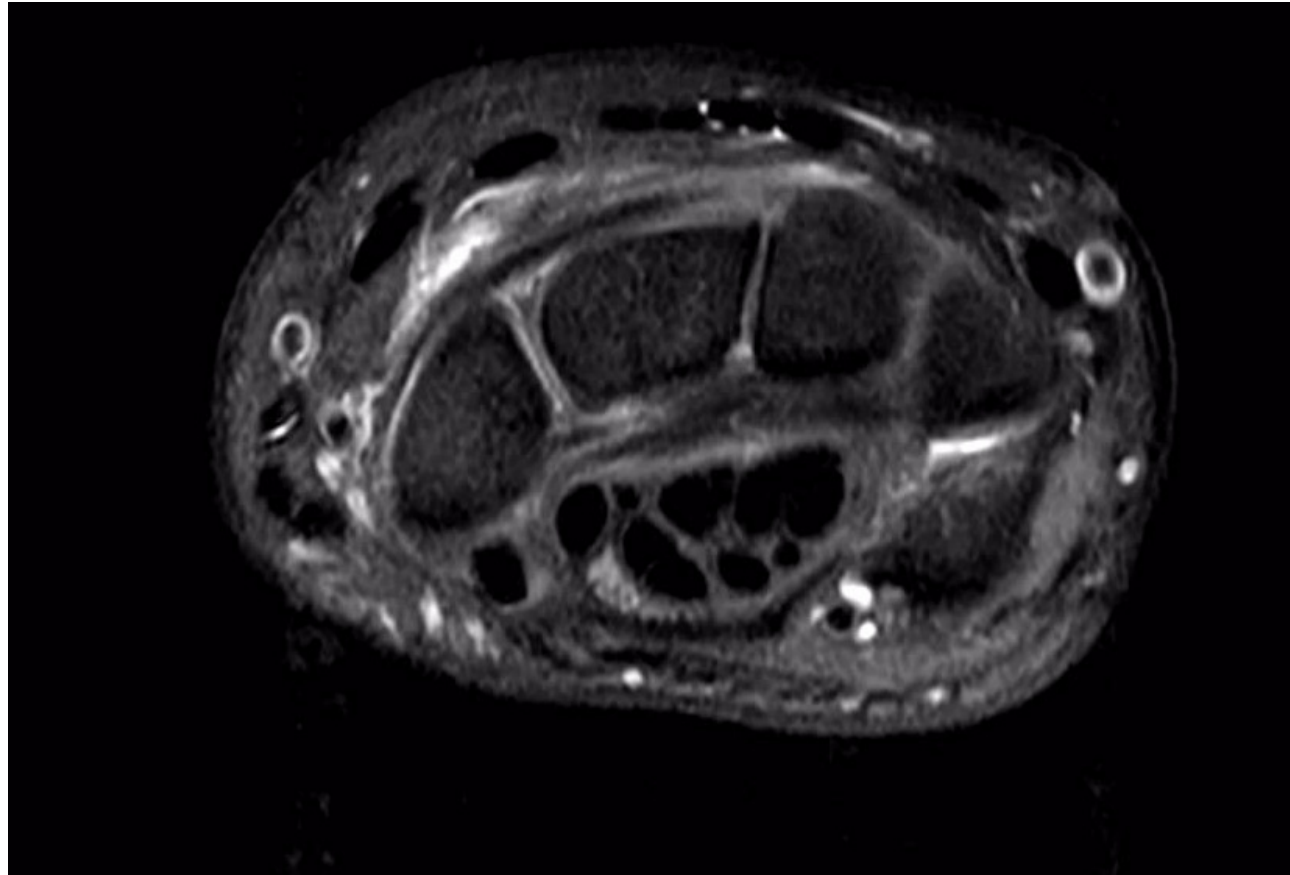
Scaphoid



Soft tissue

- Dorsal impingement
- Ulnar abutment
- SL Ligament tear
- ECU tendinopathy
- TFCC tear

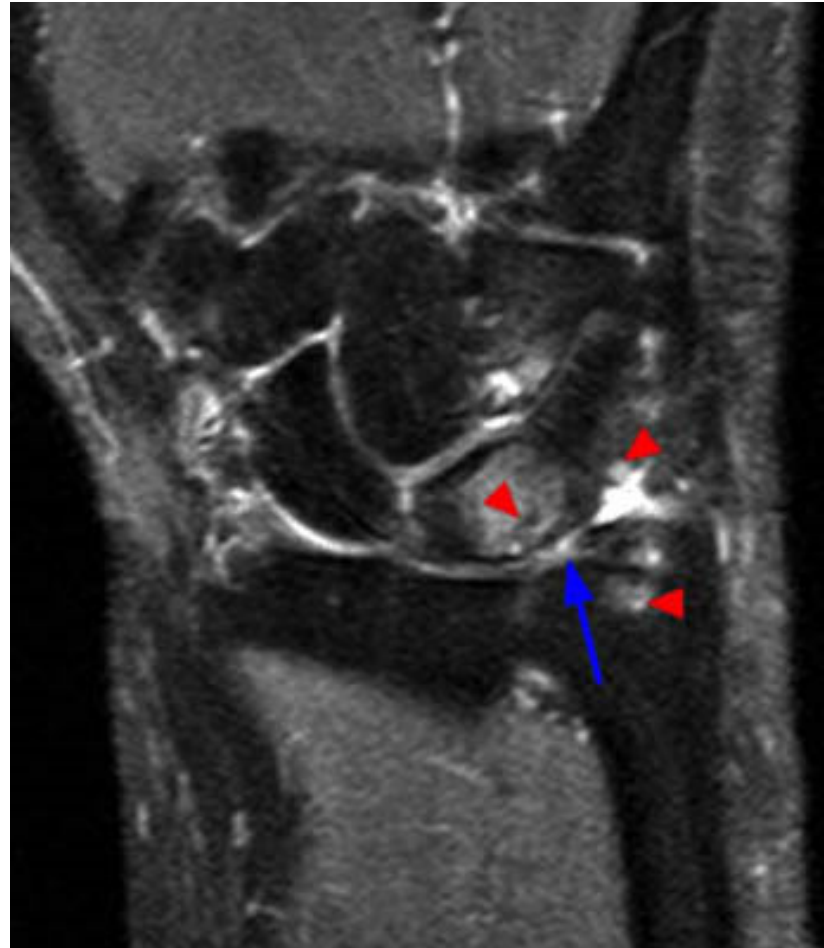Dorsal impingement - capsulitis



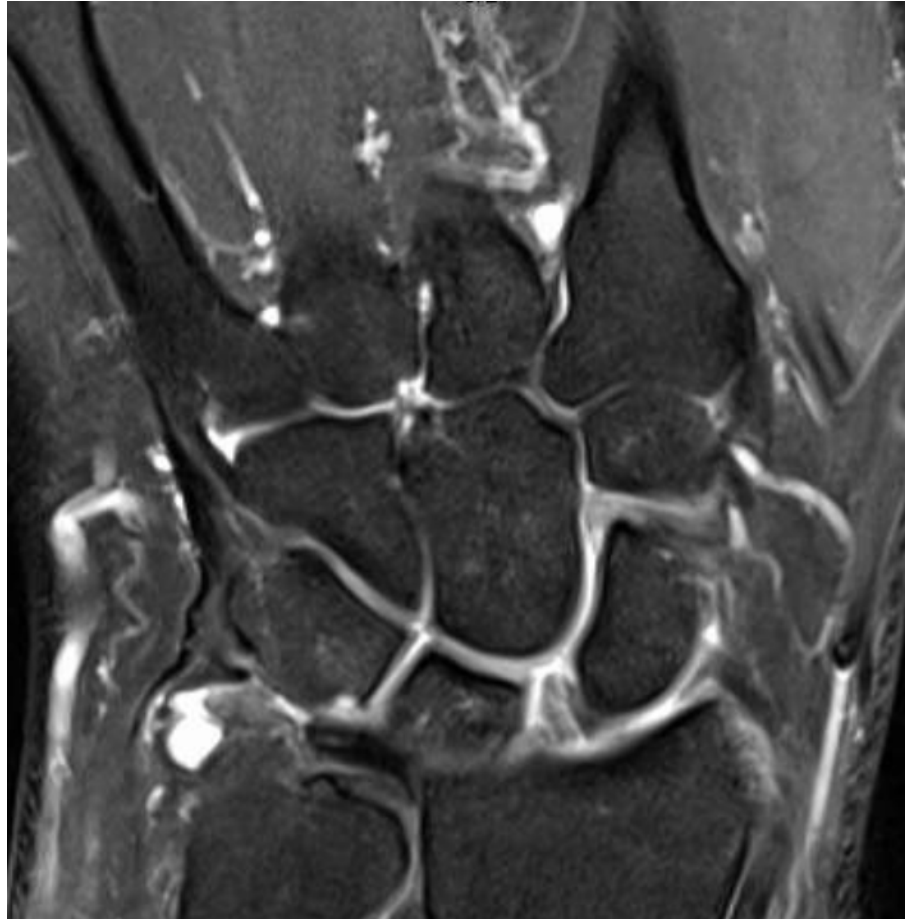Dorsal impingement – bony contusion of lunate



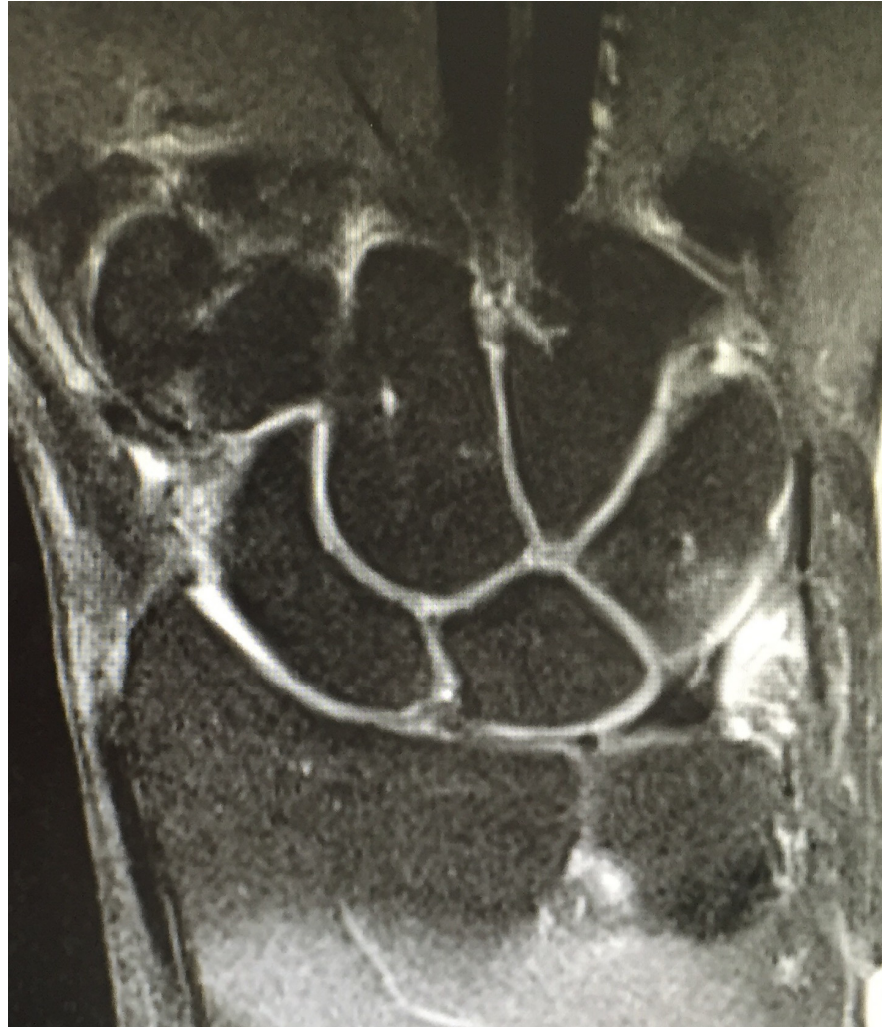Ulnar abutment



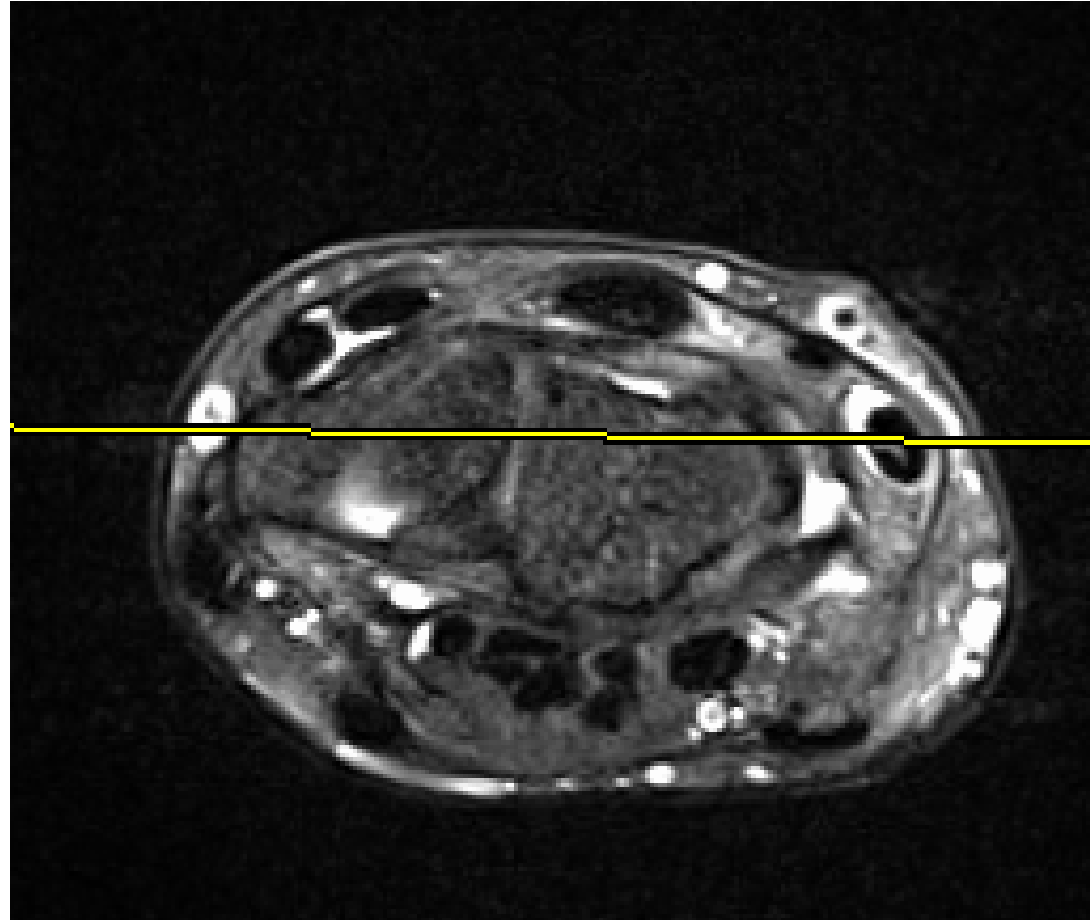
SL Ligament tear



TFCC tear



ECU Tendinopathy



SUMMARY

- BONE and SOFT TISSUE injuries
- Wide differential
- Good work up required for prognosis and treatment and to prevent long term problems

Thank you



London Sports
Orthopaedics

www.sportsortho.co.uk

london@sportsortho.co.uk

London Bridge Hospital

part of **HCA**Healthcare uk